



Preview Test: Non Viral Quiz 3

Test Information

Description

Instructions

Multiple Attempts This test allows multiple attempts.

Force Completion This test can be saved and resumed later.

▼ Question Completion Status:

Save All Answers

Save and Submit

QUESTION 1

1 points

Save Answer

In cryptococcal meningitis distinctive pathological finding is:

- Pigmentation of brainstem nuclei
- Cowdry type A intranuclear neuronal inclusions
- Small cysts in the cerebral cortex and basal ganglia
- Symmetrical calcification of the basal ganglia

QUESTION 2

1 points

Save Answer

Most common etiologic organisms are anaerobes, Streptococci and Staphylococci

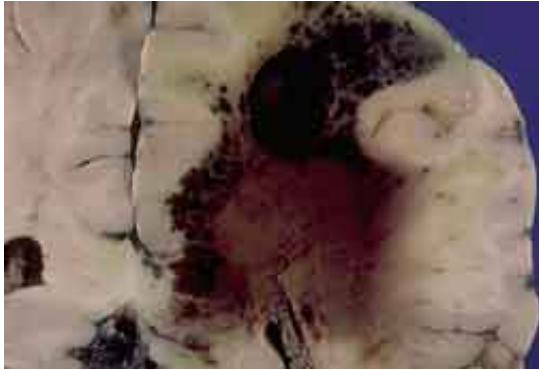
- Brain abscess
- Suppurative leptomeningitis
- Both
- Neither

QUESTION 3

1 points

Save Answer

Most likely cause of the pictured condition is:



- Syphilis
- Lyme
- Tuberculosis
- Aspergillosis
- Streptococcus Group B

QUESTION 4

1 points

Save Answer

Organisms in India ink preparation of cerebrospinal fluid

- Pneumococcal meningitis
- Herpes simplex virus (HSV-I) encephalitis
- Both
- Neither

QUESTION 5

1 points

Save Answer

Swimming in heated swimming pools or man-made lakes often precedes:

- Granulomatous amebic encephalitis due to *Acanthamoeba* spp.
- Herpes simplex encephalitis
- Toxoplasmic encephalitis
- Primary amebic meningoencephalitis due to *Naegleria fowleri*
- Eastern equine encephalitis

QUESTION 6

1 points

Save Answer

Parenchymatous neurosyphilis includes general paresis (dementia paralytica).

- True
- False

QUESTION 7**10 points****Save Answer**

Match the following definitions to the neuropathological term.

- ▾ Meningitis

- ▾ Empyema

- ▾ Cerebritis

- ▾ Abscess

- ▾ Encephalitis

A. Pocket of epidural or subdural pus

B. Exudates in subarachnoid space

C. Walled off cerebritis

D. Parenchymal infection, with chronic or acute inflammation

E. Purulent parenchymal infection

QUESTION 8**1 points****Save Answer**

Which of the following does NOT cause granulomatous infection

A. Mycobacteria

B. Fungi

C. Spirochetes

D. Bacteria

E. None of the above

QUESTION 9**1 points****Save Answer**

Brain abscesses are multiple in ~15% of cases

True

False

QUESTION 10**1 points****Save Answer**

Which of the following infections appear with Hyphal yeast forms

A. Cryptococcus

B. Coccidioidomycosis

C. Histoplasmosis

D. Blastomycosis

E. Aspergillosis

F. Mucormycosis

Click Save and Submit to save and submit. Click Save All Answers to save all answers.

Save All Answers**Save and Submit**

