



## Preview Test: Ophthalmic Pathology Quiz 2

### Test Information

Description

Instructions

Multiple Attempts This test allows multiple attempts.

Force Completion This test can be saved and resumed later.

▼ Question Completion Status:

Save All Answers

Save and Submit

### QUESTION 1

1 points

Save Answer

Epithelioid histological type most likely to metastasize.

- Retinoblastoma
- Choroidal malignant melanoma
- Toxocara canis
- Toxoplasmosis
- Glaucoma

### QUESTION 2

1 points

Save Answer

For each pair choose the one that is more strongly associated with negative prognosis in an UVEAL MELANOMA.

- spindle B morphology
- mixed spindle A and epithelioid morphology
- Equally negative

**QUESTION 3****1 points****Save Answer**

For each pair choose the one that is more strongly associated with negative prognosis in an UVEAL MELANOMA.

- penetration of sclera
- Invasion of vortex vein
- Both negative

**QUESTION 4****1 points****Save Answer**

Malignant melanoma

- Vitreous abscess rich in eosinophils
- Leukocoria (cat's eye reflex) in a 6 month old
- Most common primary intraocular neoplasm
- Bilateral granulomatous uveitis

**QUESTION 5****1 points****Save Answer**

Prognosis for malignant melanomas of the uveal tract is related to all of the following except:

- Cytology of the tumor cells
- Breaks in Bruch's membrane
- Size of the tumor
- Location of the tumor
- Extension of the tumor through scleral canals

**QUESTION 6****1 points****Save Answer**

The conjunctival melanocytic proliferation most commonly associated with subsequent development of conjunctival malignant melanoma is

- Ephelis
- Nevus
- Ocular melanocytosis
- Primary acquired melanosis

**QUESTION 7****1 points****Save Answer**

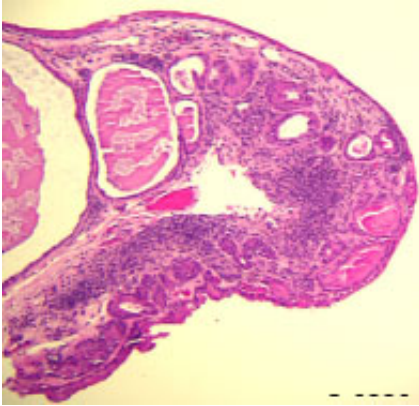The most common intraocular tumor likely to be seen in a family practice is:

- Malignant melanoma
- Metastatic carcinoma
- Malignant astrocytoma

- Retinoblastoma
- Rhabdomyosarcoma

**QUESTION 8****1 points****Save Answer**

What is the major pathologic process in this lesion?



- Inflammatory
- Malignant
- Degenerative
- Proliferative

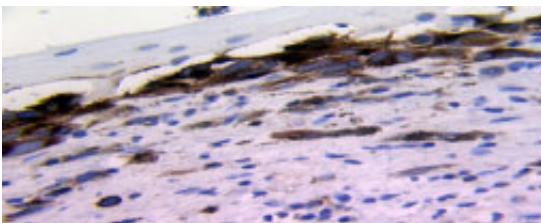
**QUESTION 9****1 points****Save Answer**

Which of the following statements about uveal melanoma is true?

- Uveal melanomas rarely metastasize
- Melanomas of the ciliary body have the best prognosis
- Metastases always occur within 2 1/2 years of treatment
- Survival is directly related to tumor size

**QUESTION 10****1 points****Save Answer**

This biopsy could represent Addison's disease.



- True
- False

*Click Save and Submit to save and submit. Click Save All Answers to save all answers.*

Save All Answers

Save and Submit